

Images in cardio-thoracic surgery

## Anomalous coronary supply from right internal mammary artery

Naresh Kumar Palli Venkata<sup>a,\*</sup>, Ramesh Babu Vedangi<sup>b</sup>,  
Prabhakar Reddy Chinta<sup>a</sup>, Ram Mohan Kanteti<sup>b</sup>

<sup>a</sup> Department of Cardiothoracic Surgery, Apollo Heart Institute, Visakhapatnam, Andhra Pradesh, India

<sup>b</sup> Department of Cardiac Anaesthesiology, Apollo Heart Institute, Visakhapatnam, Andhra Pradesh, India

Received 17 May 2010; received in revised form 25 June 2010; accepted 29 June 2010; Available online 30 August 2010

**Keywords:** Anomalous coronary artery; Interventricular groove

We report a child with tricuspid atresia, ventricular septal defect and pulmonary stenosis who was taken up for bi-directional Glenn shunt. On sternotomy, there was a vascular

pedicle from the distal right internal mammary artery (Fig. 1) continuing as anomalous coronary artery to the distal portion of the anterior interventricular groove.

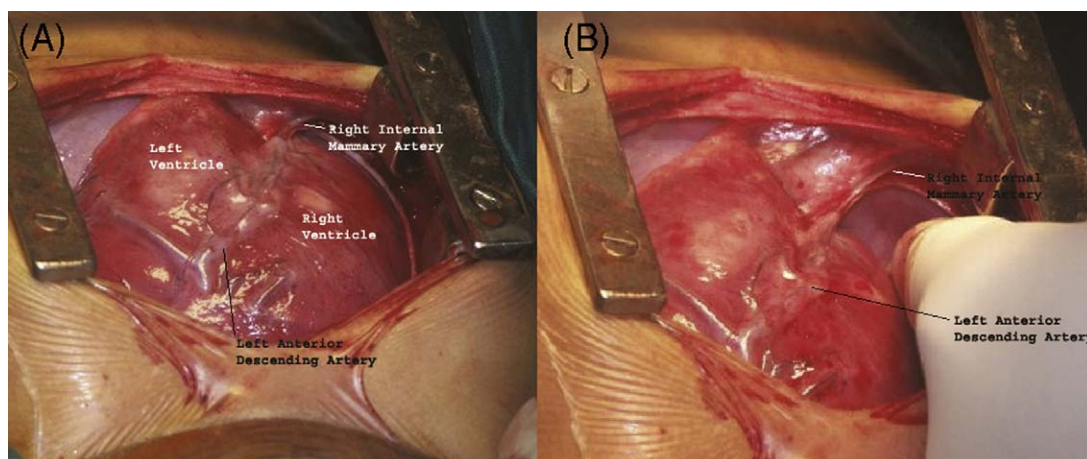


Fig. 1. Intraoperative view of anterior surface of heart showing (A) the dual blood supply of anterior interventricular groove. (B) Anomalous coronary supply to distal interventricular groove from right internal mammary artery.

\* Corresponding author. Tel.: +91 891 2727272x526; fax: +91 891 2560858.  
E-mail address: pvnaresh@hotmail.com (N.K.P. Venkata).